

American Clinical Neurophysiology Society Guideline 7: Guidelines for EEG Reporting

William O. Tatum,* Selioutski Olga,† Juan G. Ochoa,‡ Heidi Munger Clary,§ Janna Cheek,|| Frank Drislane,¶ and Tammy N. Tsuchida#

*Mayo Clinic College of Medicine, Mayo Clinic, Jacksonville, Florida, U.S.A.; †University of Rochester, Rochester, New York, U.S.A.; ‡University of South Alabama, Mobile, Alabama, U.S.A.; §Wake Forest University, Winston Salem, North Carolina, U.S.A.; ||Tulsa, Oklahoma, U.S.A.; ¶Harvard University, Boston, Massachusetts, U.S.A.; and #George Washington University, Washington, DC, U.S.A.

Summary: This EEG Guideline incorporates the practice of structuring a report of results obtained during routine adult electroencephalography. It is intended to reflect one of the current practices in reporting an EEG and serves as a revision of the previous guideline entitled “Writing an EEG Report.” The goal of this guideline is not only to convey clinically relevant information, but also to improve interrater reliability for clinical and research use by standardizing the format of EEG reports. With this in mind, there is expanded documentation of the patient history to include more relevant clinical information that can affect the EEG recording and interpretation. Recommendations for the technical conditions of the recording are also enhanced to include post hoc review

parameters and type of EEG recording. Sleep feature documentation is also expanded upon. More descriptive terms are included for background features and interictal discharges that are concordant with efforts to standardize terminology. In the clinical correlation section, examples of common clinical scenarios are now provided that encourages uniformity in reporting. Including digital samples of abnormal waveforms is now readily available with current EEG recording systems and may be beneficial in augmenting reports when controversial waveforms or important features are encountered.

Key Words: EEG, Reporting, Routine, Adult, Pediatric, Guideline.

(J Clin Neurophysiol 2016;33: 328–332)

The purpose of this guideline is to provide a standardized format for reporting the results of adult routine scalp electroencephalography (rsEEG). The moderate interobserver reliability of EEG interpretation may be partly explained by the different reporting styles utilized,¹ and there is significant variability in the observation of guidelines for EEG reporting.² Computer-based remote access technology has become more sophisticated, and video is now “routine” during rsEEG, prompting the need to revise and update the earlier ACNS guideline on “Writing an EEG Report.”³ To assist in producing useful information for clinical and research purposes, standardized terminology and following an orderly approach to EEG reporting is recommended.⁴

This guideline is designed to outline the conditions and parameters of EEG recording, including a description of the record obtained and the final impression that summarizes the EEG’s visual analysis. Its framework is intended to be useful to a clinician providing general neurologic care (including in the primary care setting) who may not be an expert on the technical aspects of EEG or on the terminology in the rsEEG report.⁵ Proper interpretation of the results reported depends on minimum technical standards for the performance of an EEG [see “Minimum Technical Requirements for Performing Clinical EEG” available at <http://www.acns.org/practice/guidelines>]. Also, it is clear that consistently higher interobserver agreement occurs when there is a forced choice paradigm using a limited set

of EEG terms.⁶ This guideline intends to provide a framework for the EEG report to address the features as normal or abnormal, with subsequent specification of their clinical importance. The significance should be evident to the clinician and the findings readily interpretable within the patient-specific context of the rsEEG recording.

When reporting specialized types of EEG (e.g., electrocerebral inactivity, or neonatal EEGs) or EEG recordings in special settings, or for prolonged durations (e.g., continuous EEG in critical illness or during video-EEG monitoring), there may be modification with special formats more applicable to those specific settings. In these situations, the description of technical details should be enhanced and more complete than is required for standard rsEEG reporting. Also, the guidelines described below are not intended to be the sole means of reporting for institutions where research indexing may apply. Guidelines have been developed by the American Clinical Neurophysiology Society (ACNS) to provide the appropriate means of recording in some special situations. Standardized reporting of clinical neurophysiologic procedures has been implemented successfully.⁷ The current guideline on “EEG Reporting” complements the earlier “Writing an EEG Report” and supplements those on non-routine recording situations and locations, available at <http://www.acns.org/practice/guidelines>.

Address correspondence and reprint requests to William O. Tatum, DO, FACNS, Mayo Clinic, 4500 San Pablo Boulevard, Jacksonville, FL 32224, U.S.A.; e-mail: tatum.william@mayo.edu.

Copyright © 2016 by the American Clinical Neurophysiology Society
ISSN: 0736-0258/16/3304-0328
DOI 10.1097/WNP.0000000000000319

FORMAT FOR REPORTING

A standard format for rsEEG reporting should include five sections: History, Technical Description, EEG Description, Impression, and Clinical Correlation.

History

The history section is an aid to interpretation of the rsEEG and should be succinct, including the reason for obtaining the recording and any relevant clinical information, as well as identification of the patient and EEG recording.

Templates for reporting EEGs should supply information and demographics about the patient. Personal information should include patient identification, including the medical record number (or other unique patient identifier) and clinical/hospital EEG record number, in addition to the last name, first name, sex, and date of birth and age at the time of the recording. The purpose of the EEG should also be documented, e.g.: (1) to evaluate patients with spells of altered consciousness, (2) to document and classify epileptiform discharges in patients with recurrent seizures and epilepsy, and (3) to evaluate patients for nonconvulsive seizures and for status epilepticus. This essential information should be entered by the person who prepares the recording for the final interpretation. Relevant clinical information should be available in the worksheet prepared by the technologist performing the EEG recording (Guideline 1: *Minimum Technical Requirements for Performing Clinical Electroencephalography*, section 3.1). This should include relevant medical history, neuroactive medications including sedatives and antiseizure drugs, neuroimaging results, note of any cranial operations, and whether previous EEGs have been performed.

Technical Description

The technical description should detail the conditions and parameters of the recording, including the date and location of acquisition and interpretation—to ensure that both are identified in case the rsEEG is interpreted days after the recording. Technical parameters should include the number of electrodes used and that the placement was in accordance with the 10 to 20 or 10 to 10 International System of Electrode Placement. Minimum standards for performing an EEG (e.g., head measurement) are required (see also, Guideline 1: *Minimum Technical Requirements for Performing Clinical EEG*). Additional electrodes (e.g., T1/T2, sphenoidal, or subtemporal electrodes), special electrodes (e.g., eye movement monitors), and modifications of the 10 to 20 and 10 to 10 System (e.g., “prime” electrodes used when there are skull defects or alteration) should be included. Special parameters (outside those recommended in Guideline 1, sections 3.3–3.6) used during post hoc review of the rsEEG should be included in this section. An example of the technical description follows: “This is a 21-channel digital EEG recording with time-locked video and single-channel electrocardiogram. Electrodes are placed according to the 10 to 20 (or 10–10) International System. Portions of this record are reviewed using bandpass filters of 2 to 35 Hz and sensitivity of 20 $\mu\text{V}/\text{mm}$.” Reporting the total recording duration may also be helpful, especially if it deviates from the minimum technical requirements for performing clinical EEG (Guideline 1, section 3.7). This is particularly advisable when it is shorter or longer than recommended for routine scalp EEG recording.

The conditions of the recording should be elucidated. A statement regarding the use of premedication should include the

drug and dose (e.g., “lorazepam 1 mg was administered before the recording”). Other conditions that can influence the EEG should also be documented, including sleep deprivation, potential dietary influences (e.g., fasting or NPO status), and modality used (rsEEG, ambulatory EEG etc.).

The patient’s state of consciousness should be documented, including if the patient is awake, drowsy, asleep, or in a compromised level of consciousness such as coma or coma-like states. This information on the patient’s state, i.e., the level of consciousness, helps guide the interpretation of the EEG and electroclinical correlation.

EEG Description

This section should include a description of the background electrocerebral activity, including all the essential characteristics of waveforms in the record, detailed as objectively as possible.

The EEG signals are complex, and extraction of clinically relevant features by visual analysis alone is subject to individual variability. Although automated software application enhances our ability to detect and quantify the power of specific bandwidths of EEG, human extraction of the clinically relevant features requires identification, integration of various bandwidths, and interpretation of the significant features in the context of the overall recording.

Description of the record should provide an objective means of analysis for review at a different time or by another interpreter. It should use technical terminology and metrics to detail the waveforms present for the duration of the recording. The aim is to provide a complete, objective, and orderly description of the state of the patient, the background activity, and the most salient features of the EEG to allow a conclusion of “normal” or “abnormal.” It should also identify and describe normal variants in addition to abnormal findings. When an abnormality is identified, the degree of abnormality should be stated.

The rsEEG description should begin with a complete description of the background activity, including the posterior dominant rhythm, additional features of the background, and special features. The description of the best *posterior dominant rhythm* in units of frequency (Hertz (Hz), or cycles per second) and amplitude (microvolts per millimeter) should be reported with the patient in the most alert state. Records obscured by artifact, recordings in infants, and some normal records may not have a clearly defined posterior dominant frequency, and the report should reflect this. Response or reactivity to external stimuli should also be noted. Subsequent *nondominant background activity* should be identified by principal frequencies, amount of each present, degrees of symmetry, location/distribution, morphology, amplitude, and rhythmicity, using the same units as for the posterior dominant frequency. Description of nondominant background activity should include beta, theta, and delta activity. Terms such as “low,” “medium,” and “high” voltage may be used but should be quantified with numerical measures.

State changes in the patient should be documented. The level of alertness, the organization of the EEG background frequency and amplitude over time, and the spatial features of the recording should be noted. Sleep patterns and architecture should

be reported to reflect all sleep stages attained during the EEG recording. Abnormal patterns such as rapid sleep cycling, sleep-onset rapid eye movements, and asymmetry or attenuation in the normal sleep elements (e.g., spindles) should be noted.

Hyperventilation and intermittent photic stimulation are routine activating procedures used to trigger abnormalities during rsEEG. They should be performed and their effects noted. When omitted, the reason for their omission should be stated. If augmentation of slowing or any epileptiform abnormalities are encountered in the rsEEG during or after activating procedures, these responses should be detailed. Documentation of poor effort with hyperventilation is relevant to rsEEG interpretation. If additional methods are used to enhance EEG abnormalities, they should also be documented.

Any special characteristics present in the background, such as voltage attenuation or augmentation, suppression-burst activity, or electrocerebral inactivity should be detailed using the same terminology used to describe the background. Descriptions should note morphology (monomorphic, polymorphic, or irregular), rhythmicity, voltage, continuous versus intermittent features, laterality (e.g., left or right; bilateral, or diffuse), region of involvement (e.g., frontal, temporal, central, parietal, occipital), and frequency (e.g., theta, delta slowing). For epileptiform and nonepileptiform features with bilateral localization, amplitude symmetry (e.g., > 50%) and synchrony (e.g., secondary bilateral synchrony vs. bilateral synchronous) should be included in the description, as well as the temporal pattern of their occurrence (e.g., bursts, prolonged runs, or sporadic).

Salient abnormal features should be noted following identification of the state and background activity. When interictal epileptiform discharges are present, one should document the location, morphology (e.g., spike, sharp, polyspike \pm slow wave), pattern (e.g., single, run, random, rhythmic, periodic), and incidence (e.g., rare, intermittent, occasional, frequent, continuous). Further description of the frequency in Hertz should be included and the pattern of occurrence (e.g., single, couplet, bursts, and a train), as well as their duration. In addition, some abnormal findings may be influenced by external stimulation (e.g., stimulus-induced, rhythmic periodic ictal-like discharges). Quantifying paroxysmal abnormalities is often expressed in a subjective manner and is relative to individual reporting designs.^{1,7}

Snapshots of a reported abnormality are encouraged to be included in the EEG report. This will help facilitate an understanding of what is being identified as an abnormality (Fig. 1). By providing a patient sample of the EEG abnormality, more universal validation will be enabled, beyond the report's text.

The presence of an electroclinical seizure or electrographic (i.e., without clinical manifestations) seizure should include description of the electrographic onset, field of propagation, and postictal period, defining the temporal and spatial characteristics and using terminology to define the location, distribution, morphology, amplitude, and rhythmicity, in addition to the duration and frequency of recurrence. When present, any clinical changes and the qualitative nature of the change should be documented, as described below under video recording.

Artifacts are present in virtually every rsEEG. They should be reported when they mimic cerebral activity, when they are unusual

or excessive (e.g., eye movements or muscle activity), when they interfere with interpretation of the record (>50% of the tracing involving >50% of the electrodes), or when they provide valuable diagnostic information (e.g., myokymia, nystagmus, etc.).

A single-channel electrocardiogram should be included in every EEG. Reporting electrocardiogram findings in the EEG description will vary and depend on the interpreter's level of expertise. Other channels such as eye movement monitors (used by some laboratories routinely), channels monitoring respiration, movement, EMG, and noncephalic monitors should be reported and described when applicable and when their significance is questioned (Guideline 1: *Minimum Technical Requirements for Performing Clinical EEG*).

Video recording is a routine part of most proprietary systems for performing rsEEG. Including video descriptions in the report is important for providing additional information involving electroclinical episodes and seizures, and in assessing artifacts. The main features should include a description of the clinical event and, when possible, terminology used by the International League Against Epilepsy seizure classification system⁸ reporting the duration, level of responsiveness/consciousness, and any intervention provided.

Impression

The impression (or interpretation) is a synthesis of the significance of the EEG findings. It is written primarily for the referring clinician and should, therefore, be as succinct as possible, and readily understandable to a clinician of any level of expertise or specialty. It should include an initial, clear summary statement as to whether it is a normal or an abnormal record. When the EEG is abnormal, the reasons why should be listed in a clear and concise line item format, in part to simplify the results for comparison among successive records. It is desirable to list the abnormalities by degrees of importance (examples: (1) a left focal temporal electrographic seizure; (2) left anterior temporal spike-and-waves; (3) left temporal delta slowing; and (4) mild slowing of the background activity).

The summary of the findings should be stated succinctly in layman's terms. When reporting several types of abnormalities, the list should be limited to the most salient findings and to the minimum number necessary to convey the significance of those findings (preferably no more than three or four). Often, the impression will be the only part of the report of major interest to the clinician, so the importance of this section is stressed. The impression should avoid confusing terminology and technical jargon, but "epileptiform discharges," including "spikes and sharp waves" are universally accepted terms.

Clinical Correlation

The clinical correlation is the ultimate translation of the EEG. It should integrate the reason for referral for the EEG and the findings to be used jointly to assist with patient management. The clinical correlation should clearly express the relevance of the findings to the clinician. Avoiding technical terminology is helpful to convey the message to the least experienced clinician

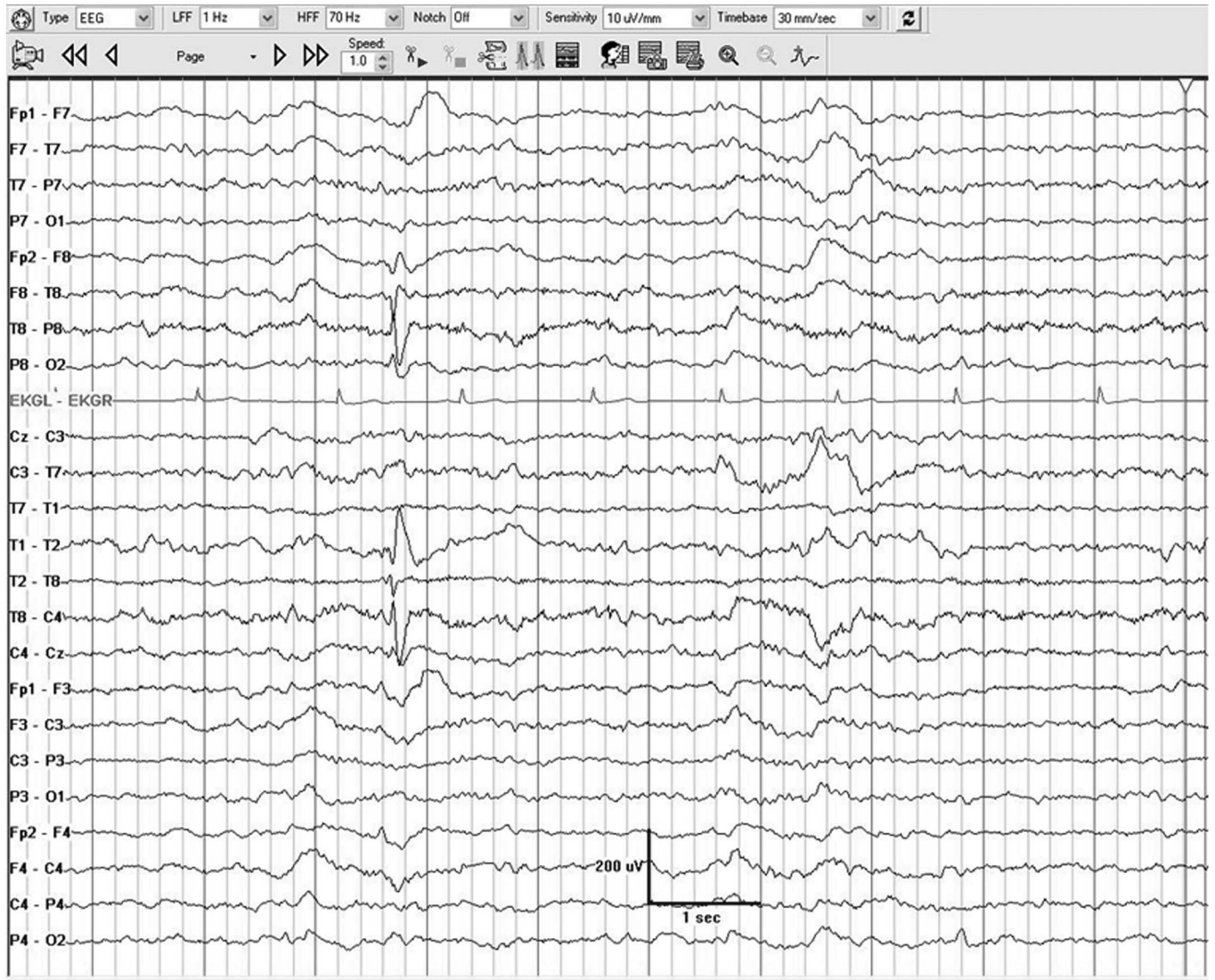


FIG. 1. A single right temporal spike-and-wave with a regional temporal field during drowsiness.

on the team caring for the patient. A good litmus test is that this section should be understandable to a general practitioner or nurse.⁴

Phrases such as “no focal or lateralizing abnormality,” “no epileptiform abnormality,” and “no electrographic seizures or evidence of status epilepticus were present” are helpful in the clinical correlation when the clinical request is explicit. Some common scenarios will be consistent from patient to patient. Although individual reporting styles vary and wording differs slightly, the following are examples of clinical correlations that may be used to express such concepts:

1. “A normal interictal EEG *does not* exclude nor support the diagnosis of epilepsy.”
2. “Focal slowing suggests an underlying lesion involving the white matter of the ipsilateral hemisphere.”
3. “Diffuse slowing of the background activity reflects a (include degree: mild, moderate, and severe) diffuse cortical dysfunction, which can be seen with toxic-metabolic or systemic causes, or neurodegenerative disorders, and also with cortical injury.”
4. “The generalized spike-and-waves seen in this tracing imply a generalized mechanism in a patient with a clinical diagnosis of epilepsy but may also represent an inherited trait independent of clinical seizures.”
5. “The left anterior temporal spikes suggest focal hypersynchrony in a patient with a clinical diagnosis of epilepsy and carry a heightened risk for focal-onset seizures of temporal lobe origin.”
6. “The suppression-burst pattern following normothermic cardiac arrest (in the absence of anesthetic drugs) suggests a poor prognosis for neurologic outcome.”

Although the clinical correlations in these cases may help standardize reporting, specific therapeutic suggestions such as “this pattern warrants antiseizure drugs” or “clinical correlation is strongly advised” should be avoided, recognizing the diagnostic limits of an rsEEG. Suggestions for further testing may be made within this section, e.g., suggesting a repeat EEG with sleep-deprivation, ambulatory EEG, video-EEG monitoring, referral to a sleep laboratory when sleep apnea is suspected, or further cardiologic evaluation when the electrocardiogram is abnormal. When previous EEGs are available, comparison of the current record to previous tracings should be included.

Note: Some electroencephalographers prefer to combine the Impression and Clinical Correlation, especially when they are simply stated and brief, e.g., “Normal routine EEG in wakefulness and in sleep.” If a combined report is used, it should start with the neurophysiologic findings (usually the abnormalities), followed by comments about the clinical significance.

This standardized reporting format is intended to maximize clear communication among different reviewers of the same patient’s rsEEG. It is hoped that this will facilitate interobserver reliability of EEG reporting for clinical care of patients and increase consistency for research studies.

DISCLAIMER

This statement is provided as an educational service of the American Clinical Neurophysiology Society (ACNS). It is based on an assessment of current scientific and clinical information. It is not intended to include all possible proper methods of care for a particular problem or all legitimate

criteria for choosing to use a specific procedure, neither is it intended to exclude any reasonable alternative methodologies. The ACNS recognizes that specific patient care decisions are the prerogative of the patient and the physician caring for the patient, based on all of the circumstances involved. The clinical context section is made available to place the evidence-based guidelines into perspective with current practice habits and challenges. Formal practice recommendations are not intended to replace clinical judgment.

REFERENCES

1. Beniczky S, Aurlen H, Brøgger JC, et al. Standardized computer-based organized reporting of EEG: SCORE. *Epilepsia* 2013;54:1112–1124.
2. Tatum WO. How not to read an EEG: introductory statements. *Neurology* 2013;80(suppl 1):S1–S3.
3. American Clinical Neurophysiology Society. Guideline 7: guidelines for writing EEG reports. *J Clin Neurophysiol* 2006;23:118–121.
4. Kaplan PW, Benbadis SR. How to write an EEG report. *Neurology* 2013;80(suppl 1):S43–S46.
5. Chatrian GE, Bergamini L, Dondey M, et al. A glossary of terms most commonly used by clinical electroencephalographers. *Electroencephalogr Clin Neurophysiol* 1974;37:538–548.
6. Gerber PA, Chapman KE, Chung SS, et al. Interobserver agreement in the interpretation of EEG patterns in critically ill adults. *J Clin Neurophysiol* 2008;25:241–249.
7. Hirsch LJ, LaRoche SM, Gaspard N, et al. American clinical neurophysiology society’s standardized critical care EEG terminology: 2012 version. *J Clin Neurophysiol* 2013;30:1–27.
8. Berg AT, Berkovic SF, Brodie MJ, et al. Revised terminology and concepts for organization of seizures and epilepsies: report of the ILAE commission on classification and terminology, 2005–2009. *Epilepsia* 2010;51:676–685.