

The American Clinical Neurophysiology Society's Guideline on Continuous EEG Monitoring in Neonates

Shellhaas RA¹, Chang T², Tsuchida T², Scher MS³, Riviello JJ⁴, Abend NS⁵, Nguyen S⁶, Wusthoff CJ⁷, Clancy RR⁵

1 Department of Pediatrics & Communicable Diseases, Mott Children's Hospital, University of Michigan, Ann Arbor, MI

2 Department of Neurology, Children's National Medical Center, Washington, DC

3 Department of Pediatrics, Rainbow Babies & Children's Hospital, Case Western Reserve University, Cleveland, OH

4 Department of Pediatrics, Texas Children's Hospital, Baylor College of Medicine, Houston, TX

5 Department of Neurology, Children's Hospital of Philadelphia, University of Pennsylvania, Philadelphia, PA

6 Centre Hospitalier Universitaire d'Angers, Angers, FR

7 Division of Neonatology, Hammersmith Hospital, Imperial College, London, UK

Corresponding Author:

Renée Shellhaas, MD MS

L3215 Women's Hospital

1500 E Medical Center Dr.

Ann Arbor, MI 48109-5203

Email: shellhaa@med.umich.edu

Fax: 734-763-7551

Telephone: 734-936-4179

Funding disclosure: none.

Conflicts of interest: none.

Running title: Neonatal EEG Monitoring Consensus Statement

Introduction

This document offers preferred methods and indications for long-term, conventional electroencephalography (EEG) monitoring for selected, high risk neonates of post-menstrual age less than 48 weeks. The authors recognize that there may be significant practical barriers to the implementation of these recommendations for many caregivers and institutions, particularly with regard to the availability of equipment, and technical and interpretive personnel. A wide range of clinical circumstances dictates the implementation of EEG monitoring, frequency of EEG review, and the subsequent treatment of seizures or EEG background abnormalities detected by neonatal EEG. Consequently, this document should be considered as an expression of idealized goals and not as a mandated standard of care.

Indications for conventional EEG monitoring in neonates

1) Use of long term EEG monitoring to evaluate for electrographic seizures

- a) Differential diagnosis of abnormal paroxysmal events: EEG monitoring can be used to clarify whether sudden, stereotyped, unexplained clinical events are seizures. Since epileptic seizures are common in acutely ill newborns¹⁻⁶, are difficult or impossible to accurately identify and quantify by visual inspection alone^{7,8}, may contribute to or amplify adverse outcomes^{9,10}, and are potentially treatable by the administration of anti-seizure medications¹¹⁻¹³, the largest role of EEG monitoring is the surveillance for and prompt treatment of electrographic seizures. Clinical signs such as abrupt, repetitive, or abnormal appearing movements, atypical behaviors or unprovoked episodes of autonomic dysfunction may be the outward clinical expression of neonatal seizures (Table 1). It is acknowledged that the yield of EEG monitoring to confirm the epileptic basis of isolated, paroxysmal *autonomic* signs (e.g. isolated paroxysmal increases in heart rate or blood pressure) is low^{1,14}; however, when episodes of autonomic dysfunction are the result of seizures, they can only be accurately identified by EEG monitoring.

Table 1: Examples of sudden, stereotyped clinical events that may raise the suspicion for neonatal seizures

| |
|--|
| ▪ Focal clonic or tonic movements |
| ▪ Intermittent forced, conjugate, horizontal gaze deviation |
| ▪ Myoclonus |
| ▪ Generalized tonic posturing |
| ▪ “Brainstem release phenomena” such as oral-motor stereotypies, reciprocal swimming movements of the upper extremities or bicycling movements of the legs |
| ▪ Autonomic paroxysms such as unexplained apnea, pallor, flushing, tearing, and cyclic periods of tachycardia or elevated blood pressures |

- b) Detection of electrographic seizures in selected high risk populations: In many high risk populations, neonatal seizures are common, but most are *subclinical* (i.e., they have no outwardly visible clinical signs and may only be identified by EEG monitoring). Such electrographic seizures are referred to by various names,

such as *non-convulsive, silent, occult, or electrographic-only* seizures^{7, 8, 15, 16}. The proportion of subclinical seizures is lowest among those who are naïve to anti-seizure medication treatment^{7, 17, 18}. However, once anti-seizure medications are administered, up to 58% of treated neonates exhibit electroclinical uncoupling, in which the clinical signs of their seizures vanish despite the persistence of subclinical electrographic seizures¹⁶.

- a) Clinical settings in which to suspect neonatal seizures: Infants who are at high risk for acute brain injury, those with demonstrated acute brain injury, and those with clinically suspected seizures or neonatal epilepsy syndromes are at high risk for electrographic seizures and should be considered as candidates for long term EEG monitoring (Table 2). Furthermore, neonates in high-risk clinical settings who are iatrogenically paralyzed by the administration of neuromuscular blocking agents, precluding accurate neurological examination, may require EEG monitoring to accurately detect seizures.

Table 2: Examples of high risk clinical scenarios which may lead to consideration of long-term neonatal EEG monitoring

| Examples of clinical scenarios conferring high risk of neonatal seizures |
|--|
| <ul style="list-style-type: none"> ▪ Clinical syndrome of acute neonatal encephalopathy <ul style="list-style-type: none"> ▪ Neonatal depression from suspected perinatal asphyxia (chronic or acute) ▪ Following cardiopulmonary resuscitation ▪ Cardiac or pulmonary risks for acute brain injury and clinical encephalopathy <ul style="list-style-type: none"> ▪ Significant respiratory conditions, such as severe persistent pulmonary hypertension ▪ Need for extracorporeal membrane oxygenators (ECMO) ▪ Congenital heart defects requiring early surgery using cardiopulmonary bypass ▪ CNS infection <ul style="list-style-type: none"> ▪ Laboratory confirmed meningoencephalitis ▪ Suspected CNS infection, such as clinical evidence in setting of maternal chorioamnionitis, funisitis, group B streptococcus or HSV colonization ▪ CNS trauma <ul style="list-style-type: none"> ▪ Intracranial subarachnoid, subdural, or intraventricular bleeding ▪ Clinical encephalopathy <u>and</u> suspicion for CNS injury, e.g. maternal trauma, traumatic delivery, prolonged 2nd stage of labor, or suspected non-accidental trauma ▪ Inborn errors of metabolism (suspected or confirmed) ▪ Perinatal stroke (suspected or confirmed) ▪ Sinovenous thrombosis (suspected or confirmed) ▪ Premature infants with additional risk factors <ul style="list-style-type: none"> ▪ Acute high grade intraventricular hemorrhages ▪ Very low birth weight with clinical concern for encephalopathy ▪ Genetic/Syndromic disease involving CNS <ul style="list-style-type: none"> ▪ Cerebral dysgenesis on neuroimaging |

- Dysmorphic features or multiple anomalies with microcephaly

- b) Monitoring for seizure recurrence during or after weaning anti-seizure medications: Although there are no published data (as of February, 2011) to support or refute this practice, some centers utilize EEG monitoring during and after withdrawal of anti-seizure medications to screen for recurrent seizures. The committee members agreed that indications for EEG monitoring during or after medication withdrawal depend on the underlying etiology of the neonatal seizures. For example, seizures in neonates with acute acquired brain injury (e.g. arterial ischemic stroke or hypoxic-ischemic encephalopathy) are unlikely to recur soon after the resolution of the acute phase. Conversely, neonates at high risk for seizure recurrence (e.g. cerebral dysgenesis or malformations, tuberous sclerosis or neonatal epilepsy syndromes) may have a relapse of seizures if medications are withdrawn. Therefore, the decision to monitor (or not to monitor) as anti-seizure medications are adjusted must be tailored to the individual's clinical circumstance.
- c) Monitoring burst suppression: EEG monitoring should be used to quantify the duration of the interburst periods in those who undergo deliberate pharmacological suppression of EEG, such as with pentobarbital or midazolam for treatment-resistant status epilepticus, as well as to detect break-through seizures. In other contexts, such as severe metabolic encephalopathies due to neonatal citrullinemia with marked hyperammonemia, the duration of the interburst intervals progressively declines as the hyperammonemia is corrected by medical intervention¹⁹.

2) Use of long term EEG monitoring to judge the severity of an encephalopathy

There are broader applications for neurophysiological monitoring in the neonatal intensive care setting beyond seizure detection alone²⁰. Most types of neonatal encephalopathy are represented by a spectrum of severities. This is reflected in the familiar Sarnat encephalopathy scale in which the clinical grades of encephalopathy are ranked from stage 1 to 3, depending on the depth of abnormalities of mental status, neuromuscular tone and activity, and muscle stretch or bulbar reflexes²¹. Likewise, EEG background abnormalities parallel the degree and course of encephalopathy. As such, EEG backgrounds may demonstrate subtle or mild abnormalities in those with modest degrees of acute encephalopathy, moderate background abnormalities in those with intermediate severity injuries, or severe abnormalities in those with profound acute brain injuries²². Thus, serial assessment of the EEG background serves the role of following the dynamic, evolving character of an acute encephalopathy as well as providing a sensitive and specific prognostic tool for predicting survival or long term disability.

- a) EEG monitoring for assessment of background abnormalities during acute neonatal encephalopathy: Continuous or serial EEG studies offer important information regarding the degree of neonatal encephalopathy. In acute encephalopathies that occur at or near the time of birth, severe background abnormalities (e.g. burst suppression, low voltage invariant, isoelectric, asynchrony, asymmetry and others) define the functional extent of the global brain injury and are reliable prognostic indicators (reviewed in ²²). Major EEG background disturbances resolve or evolve over days to weeks into alternate expressions of persistent brain disorders, as the infant is tracked from the acute through the convalescent phases of an acute encephalopathy. Therefore, obtaining serial EEG studies can assist the treating clinicians in providing prognostic information for the encephalopathic newborn. The most appropriate timing of these recordings depends on the clinical circumstances.

It is prognostically favorable to see the return of sleep state cycling after acute hypoxic ischemic encephalopathy (HIE). As recognizable state transitions return after the acute phase of an encephalopathy, a routine one hour recording may be incapable of documenting both active and quiet sleep segments since many lack the normal one hour neonatal ultradian sleep rhythm ²³. Consequently, abnormalities of the neonatal EEG/sleep cycle may be more reliably detected during prolonged (3-4 hours) or serial recordings. Finally, the use of an expanded array of recording electrodes like those used in routine neonatal EEG may be required, including relevant polygraphic data (e.g. electrocardiogram, respirations, oxygenation, extraocular movements and electromyogram). Such comprehensive multichannel recordings most accurately localize regional or hemispheric cerebral activities, stage neonatal sleep, describe specific behaviors (possibly with concurrent video monitoring) and detect artifact.

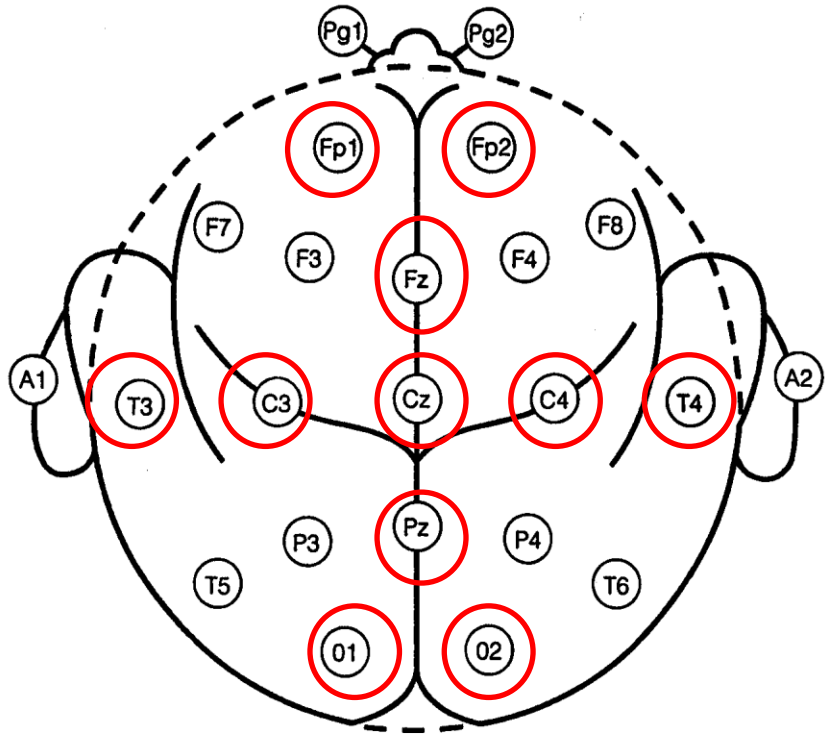
- b) EEG monitoring for assessment of background abnormalities following neonatal encephalopathies of prenatal origin: Many causes of neonatal encephalopathy discovered at birth have a significant *prenatal* origin or contribution²⁴. Consequently EEG examinations immediately after birth may miss the most abnormal findings that are ordinarily used to formulate an estimate of prognosis. Indeed, some non-specific normalization of the background can occur even in the wake of a severe injury. In those who have already transformed to a subacute or chronic phase of encephalopathy by the time of birth, EEGs may already have evolved to express only milder features of neurophysiological dysfunction. In the future, computer analyses of EEG/sleep recording may augment our ability to detect and classify these more subtle expressions of dysfunction, using frequency and time-dependent analytic strategies ²⁵. Current research is evaluating the utility of multi-channel EEG /sleep recordings in conjunction with computer-generated evoked potential findings (i.e., visual, auditory, somatosensory) to offer both region-specific diagnostic information throughout the neuroaxis involving specific neuronal networks as well as relevant prognostic information ²⁶.

- c) Dysmature EEG examinations: The concept of dysmaturity has evolved in the specific context of serial EEG examinations in very premature infants. In general, the appearance of a premature infant's EEG background is determined solely by their postmenstrual age, obtained by adding the estimated gestational age to the legal age. Skilled EEG readers can estimate a patient's postmenstrual age within ± 2 weeks by assessing the development of sleep states, number and distribution of delta brushes, type of discontinuity in quiet sleep and the appearance of specific transients such as encoches frontales (a.k.a frontal sharp transients). Some very premature babies, especially those with severe lung disease, have a chronic encephalopathy during which postnatal brain development may be delayed, resulting in anatomical and functional immaturity. Correspondingly, they may show EEG *dysmaturity* detected by serial EEG examinations. For example, if a 36 week postmenstrual age infant displays the overall EEG characteristics typical of a 32 week postmenstrual age infant, the gap between the actual postmenstrual age and the patient's age suggested by their EEG characteristics is physiologic evidence of dysmaturity. In general, studies of prognosis based on EEG findings utilize the results of routine-length EEGs rather than long-term EEG monitoring. In the case of *chronic* injuries, which may evolve over extended time periods, more pervasive electrographic/polygraphic disturbances are more easily diagnosed using multiple, serial EEG/sleep recordings, of sufficient duration to capture both wakefulness and sleep, if such state changes exist, with important prognostic implications^{27, 28}.

Procedures for neonatal EEG monitoring

- a) The Committee endorses the American Clinical Neurophysiology Society's Guidelines on the Minimum Technical Standards for pediatric EEG²⁹. Electrodes should be placed according to the International 10-20 system, modified for neonates (Figure 1). A full array of electrodes may be placed, according to the International 10-20 system, but this is not mandatory. In addition to scalp electrodes, extracerebral channels including electrocardiogram (EKG) and respiratory channels, should be utilized. Eye leads (for electro-oculogram) and surface electromyography (EMG) leads are often useful but are not universally required.

Figure 1: The International 10-20 System for electrode placement, modified for neonates. Electrode positions circled in red are included in the typical neonatal montage. Note that some laboratories use an alternate location for the position of the frontal polar electrodes. The neonatal electrode designation "FP₃" is located halfway between the conventional electrode locations of FP₁ and F₃. Similarly, the neonatal electrode position "FP₄" is halfway between the conventional electrode positions of FP₂ and F₄. Note also that not all laboratories utilize the Pz electrode. Alternate terminology designates "FP" electrodes as "AF", T_{3/4} as T_{7/8}



- b) Conventional EEG is typically recorded with surface electrodes. Silver and gold electrodes are available. The former provides lower impedance while the latter are compatible with magnetic resonance imaging. Although some centers use needle electrodes for neonatal EEG monitoring, this is not a mandated practice. Computerized tomography (CT) and magnetic resonance imaging (MRI)-compatible EEG electrodes are becoming available, but require administrative approval and acceptance by individual radiology departments.
- c) Several neonatal EEG montages are in common use. Typically a single neonatal montage is adequate for long-term monitoring. Examples are listed in Table 3.

Table 3: Sample neonatal recording and interpretation montages

| Montage 1* | Montage 2* | Montage 3* |
|------------|------------|------------|
| FP1-T3 | FP1-T3 | FP1-C3 |
| T3-O1 | T3-O1 | C3-O1 |
| FP2-T4 | FP1-C3 | FP1-T3 |
| T4-O2 | C3-O1 | T3-O1 |
| FP1-C3 | Fz-Cz | FP2-C4 |
| C3-O1 | Cz-Pz | C4-O2 |
| FP2-C4 | FP2-C4 | FP2-T4 |
| C4-O2 | C4-O2 | T4-O2 |
| T3-C3 | FP2-T4 | T3-C3 |
| C3-CZ | T4-O2 | C3-CZ |
| CZ-C4 | T3-C3 | CZ-C4 |

| | | |
|-------------------------|-------------------------|-------------------------|
| C4-T4 | C3-CZ | C4-T4 |
| FZ-CZ | CZ-C4 | |
| CZ-PZ | C4-T4 | |
| Electrocardiogram | Electrocardiogram | Electrocardiogram |
| Chest wall respirations | Chest wall respirations | Chest wall respirations |

*Additional channels may be added for eye leads, chin electromyography, and nasal thermistor respiration measurements.

- d) Concurrent conventional EEG and reduced electrode EEG monitoring (amplitude-integrated EEG): When single channel amplitude-integrated EEG (aEEG) recordings are obtained in isolation, the recommended electrode locations are P3 and P4 because they overlie the apices of the cerebrovascular watershed zones³⁰ and have been shown to detect more seizures than frontal electrodes³¹. When reduced channel aEEG is obtained simultaneously to complement ongoing conventional EEG monitoring, P3 and P4 may be added to the conventional recording montage. Alternatively, the nearby C3 and C4 electrodes may be substituted by electrode splitters. When two-channel aEEG is used to complement conventional EEG, the electrode pairs C3/P3 and C4/P4 are most commonly recommended. Single or dual channel aEEG can provide useful information regarding the neonatal EEG background for the selected central or parietal regions, although the data provided by conventional EEG are more nuanced and allow detailed evaluation of particular brain regions. aEEG is less sensitive for the detection of neonatal seizures³²⁻³⁴ compared to long term monitoring by conventional EEG. Utilizing multichannel aEEG (with 8 channels) may improve seizure detection^{35, 36}. This is further discussed in the subsequent digital trending and analyses section.
- e) Use of synchronized video monitoring: Synchronized video is strongly *recommended* for characterization of events and is *often helpful* in assessing for artifacts that might mimic electrographic seizures. Such artifacts include: chest physical therapy, patting, sucking on a pacifier or endotracheal tube, high frequency or conventional ventilation artifacts, ECMO pump artifacts, electrocardiogram, pulsatile fontanelle, or other environmental or electrical interference.
- f) Importance of a bedside observer: Even when video is being recorded, a bedside observer who can document the occurrence of key clinical events electronically or in a bedside log and push the EEG event button is *recommended*. If time-locked video recording is not available, then a bedside observer is *required*. Key events could include suspected seizures or clinical events, chest physical therapy, neuroactive drug administration, the initiation of hypothermia or rewarming, and similar pertinent occurrences that could influence the appearance of the EEG. While electrographic seizures can be identified without a bedside observer, non-seizure events are difficult to recognize without observer documentation. Bedside observers can enter a text description for the event on the digital EEG file at the time of the event. Alternatively, the bedside log should contain a description of the events, along with the date and time.

- g) Duration of EEG recording: The indication for EEG evaluation determines the most appropriate duration of EEG monitoring and should be modified as appropriate by the results of the EEG examination.
- a. EEG background assessment requires a minimum of 1-hour of recording time to allow analysis of sleep-wake cycling, if present.
 - b. The Committee *recommends* that neonates at *high risk* for seizures (see Table 2) be monitored with conventional EEG for 24-hours to screen for seizures. Seizures suspected by aEEG were documented in over half of term neonates with HIE who fulfilled criteria for selective head cooling within 6 hours of birth³ and studies of neonates undergoing EEG monitoring during therapeutic hypothermia for HIE have also demonstrated a high incidence of seizures³⁷. After newborn heart surgery, seizures occurred at a mean of 21 hours (range 10-36 hours) postoperatively¹ and always within 22 hours in another more heterogeneous group of high-risk neonates³⁸. Published data indicate that seizures may occur even in the presence of a normal or mildly abnormal EEG background^{39,40}. Therefore, for *high-risk* (as described in Tables 1 and 2) infants, a 1-hour EEG is considered inadequate to screen for seizures. In consultation with a neurologist, some lower risk infants may be identified and at the discretion of the clinical team EEG monitoring may be appropriately discontinued sooner than 24 hours.
 - c. If seizures are detected, it is *recommended* that EEG monitoring continue until the patient has been seizure-free for at least 24-hours, unless in consultation with a neurologist a decision is made to discontinue monitoring earlier. While there are no published data on the recurrence of seizures after 24-hours of seizure-freedom (as of March 2011), this is a customary practice among child neurologists.
 - d. Although contemporary published data on this topic are not available, the Committee *recommends* that EEG monitoring for the differential diagnosis of suspicious clinical events should continue until multiple *typical* events are captured. If an adequate sample of *typical* events are captured and lack an associated electrographic seizure, then monitoring for that purpose may be discontinued. Likewise, if the clinical episodes resolve spontaneously, EEG monitoring may be discontinued.

Training of caretakers

Appropriate neonatal EEG monitoring requires a team of trained caretakers, including nurses, EEG technologists, neonatologists, pediatricians, neurologists, and clinical neurophysiologists with training in neonatal EEG acquisition and interpretation.

EEG interpretation and reporting

- a) EEG interpretation by the clinical neurophysiologist: We recognize that a wide range of clinical circumstances influence EEG review practices and treatment strategies as dictated by institutional resources. Remote access to EEG tracings facilitates timely interpretation. The first hour of EEG recording should be interpreted as soon as possible by the clinical

neurophysiologist and the results conveyed to the treating clinicians. The frequency of subsequent review depends on the clinical scenario. At a minimum, the EEG tracing should be reviewed by the clinical neurophysiologist at least twice per 24-hour epoch, and more often as clinically indicated. The EEG should be re-reviewed according to clinical circumstances (e.g. if bedside clinicians report the occurrence of a suspicious event of interest or after a therapeutic intervention has been implemented or adjusted to evaluate for treatment response).

- b) EEG review by the EEG technologist and nursing staff: Ideally, the EEG technologist should remain at the bedside for the first hour of recording to ensure a high quality recording and to make note of relevant clinical signs. Thereafter, the EEG technologist should re-evaluate the quality of the EEG recording frequently and adjust recording leads as necessary. The bedside nurse should also evaluate the quality of the recording periodically and should contact the technologist if the tracing is suboptimal.
- c) Reporting EEG results: Results of the EEG monitoring should be communicated formally to the treating clinicians at least daily. Interim verbal reports should be provided to the clinical team as needed. Written reports should be part of the medical record and should be completed daily, including assessment of the EEG background, seizures, and push-button events. This recommendation applies to both conventional and reduced-montage EEG recordings (e.g. amplitude-integrated EEG; aEEG).

Data retention and storage

- a) Data storage: Ideally, EEG data should be recorded and stored in nonproprietary or publicly available formats to insure that the tracings can be viewed using various manufacturers' software and/or equipment (for details, see American Clinical Neurophysiology Society Guidelines, available at www.acns.org). In addition, it should be possible to provide a disk upon request which includes the EEG recording and appropriate review software.
- b) Data retention: Each EEG monitoring center should review their institutional and/or state guidelines for their mandated duration of data storage. Where institutional and/or state guidelines are lacking, discussion with the center's legal counsel is warranted. Typically, it is medically indicated to archive EEG recordings for the immediate future, and regulations may require the data to be retained for 7 years or until the patient reaches 18 years of age, whichever is longer. Data storage guidelines apply to all formats of EEG recordings, regardless of the number or type of electrodes applied. Therefore, data derived from reduced-montage EEG devices (e.g. aEEG) should be stored according to the same regulations which apply to conventional EEG. Trend data need not be stored separately, since they can be recreated from the original EEG recording.

Digital Trending and Analyses

Trend analyses represent a variety of mathematical signal transformations of one or more channels of EEG, which are then displayed on a compressed time scale. Trends

provide a condensed overview of prolonged EEG recordings, allowing the interpreter to view a compressed representation of an extended epoch of EEG recording in a single graph. They are useful in summarizing long term trends, the presence of sleep-wake cycling and targeting specific regions of interest for detailed review (e.g. to evaluate for suspected seizures) during prolonged recordings. However, time compression may result in obscuration of brief clinical or EEG events. Conventional EEG is usually interpreted on a time scale of 15 to 30mm of recording per second. In contrast, the typical display of aEEG, is 6cm per hour, thus compressing the time scale of conventional EEG by a factor of up to 900:1. The mathematical transformation used depends on the type of information desired. Some trending approaches are commercially available and others exist only in the research realm. It is beyond the scope of this document to exhaustively list or examine all available digital trending algorithms, particularly as this is an evolving field and few data directly pertinent to neonates are available.

In the newborn, digital trending has been used mainly to analyze the EEG background, and seizure detection has been a secondary goal. . The most commonly employed digital trends are discussed below. Except for aEEG, few data exist to support or refute their use for neonatal monitoring. However, since many of these modalities are used concurrently with conventional EEG monitoring (e.g. digital trending is displayed at the bedside while full-array EEG is recorded) and aEEG is a widely-used monitoring tool in neonatal intensive care units, the committee reviewed the modalities below.

a) Amplitude-integrated EEG (aEEG) is the most commonly used digital trend for newborns and its use has been integrated as a customary practice for assessment of EEG background in many intensive care nurseries⁴¹⁻⁴⁴). This trending modality modifies the raw EEG by filtering frequencies less than 2Hz and more than 15Hz, rectifying and smoothing the signal, and uses a semilogarithmic amplitude compression (with a linear display for 0-10 μ V and logarithmic display for 10-100 μ V) before displaying it in a time-compressed manner with 6cm/hour of recording, as previously mentioned. Full technical details of aEEG are provided in excellent reviews^{30,45}. Compared to management based on clinical seizure detection alone, use of aEEG has been shown to reduce the total seizure duration in neonates⁴⁶.

The original aEEG monitors used a single channel of “raw” EEG (filtered as described above) derived from EEG leads placed in the parietal (P3 and P4) positions. The parietal region was originally selected because it is over the cerebrovascular watershed, an area at high risk for acquired injury. However, the adjacent C3 and C4 channels probably provide comparable data for single channel aEEG. Most contemporary machines now allow display of dual channel recordings (e.g. C3 \rightarrow P3 and C4 \rightarrow P4), along with the raw EEG from which the aEEG signals are derived, providing the opportunity to detect interhemispheric asymmetries. Because seizure detection is impeded by artifact and inadequate ability to detect ictal patterns from the frontal electrodes, this committee discourages frontal electrode placement for aEEG recordings³¹.

Conventional video-EEG monitoring is the gold standard for neonatal seizure detection and quantification and should be used whenever available for seizure detection and differential diagnosis of abnormal appearing, paroxysmal clinical events. It is the ideal tool to measure the exact number and duration of seizures, their site(s) of onset and spatial patterns of migration. However, if there are obstacles in obtaining conventional

EEG monitoring, then aEEG can be a useful, initial complementary tool. Because of data showing poorer sensitivity and specificity for seizure detection,³²⁻³⁴ single and dual channel aEEG alone are not recommended for this purpose if conventional EEG is available. If seizures are suspected on aEEG, this committee recommends that conventional EEG monitoring, if available, should begin as soon as possible to confirm and refine the electrodiagnosis. aEEG utilizing multiple channels or averaged groups of electrodes (hemispheric or regional) can be considered as an adjunct to conventional EEG monitoring.^{35,36} Some neonatal intensive care units record conventional EEG, but display aEEG on the bedside monitor, to facilitate real-time bedside interpretation while allowing subsequent confirmation by neurophysiologists interpreting the conventional EEG recording.

The sensitivity of aEEG for neonatal seizure detection is limited. Using single channel aEEG, without raw single channel EEG for confirmation, individual seizure detection is less than 50%^{32,33} and depends on the interpreter's level of expertise. Although the addition of a second aEEG channel along with the ability to review raw EEG improves the sensitivity (up to 76%, with 78% specificity, in one study using aEEG experts³⁴), seizure detection remains difficult with this tool³⁴. The committee acknowledges, however, that it is unknown whether such suboptimal seizure detection impacts clinical outcomes. Compared to management based on clinical seizure detection alone, use of aEEG has been shown to reduce the total seizure duration in neonates⁴⁶.

aEEG for background assessment (rather than seizure recognition) has been shown to provide early prognostic information in infants with hypoxic-ischemic encephalopathy⁴⁷⁻⁵⁰. aEEG may be useful for risk stratification for clinical trials^{3,51}, although some argue against its use for the determination of study eligibility for therapeutic hypothermia protocols⁵².

b) Density spectral array (DSA) displays EEG spectral power as a gray-scale or color plot, with time on the x-axis, frequency on the y-axis, and the power in gray-scale or color-scale. Power can be calculated for a specific set of electrodes, or can be averaged over a group of electrodes (e.g. a cerebral quadrant or hemisphere). Analysis of the raw EEG is important to exclude artifact, which causes increased activity in all frequencies, and thus translates to increased power, mimicking seizures. This trend is preferred by many neurophysiologists and neurointensivists and is used as an adjunct to standard EEG recording in critically ill adults and children. Further study is required before the committee can endorse widespread clinical use of DSA for neonatal seizure detection.

c) Envelope Trend (ET) displays the median amplitude of successive EEG epochs. Using median amplitudes reduces the appearance of transient high amplitude waveforms which are commonly caused by artifacts. This modality can be used to identify some seizures, although movement artifact during an electroclinical seizure may contaminate the ET. Furthermore, brief and slowly evolving seizures remain very difficult to detect with ET⁵³. Further study is required before the committee can endorse widespread clinical use of ET for neonatal seizure-detection.

e) Seizure detection and background grading algorithms are a topic of intense ongoing research (e.g.^{54,55}). Data suggest that accurate seizure detection requires neonatal-specific algorithms, which many investigators are working to develop.

However, current commercially-available algorithms have poor sensitivity and specificity.

Legal implications of the present consensus statement

This consensus statement is offered as a preferred set of goals for neonatal EEG monitoring and is not intended as a mandated standard of care. The Committee underscores the lack of evidence that neonatal EEG monitoring, seizure identification, or treatment of seizures, impacts long-term clinical outcomes. Therefore, while there is general consensus that longitudinal characterization of the EEG background, along with seizure identification and management are important, the Committee emphasizes that any EEG recording is better than none at all and that delayed detection of seizures is better than no recognition of these events. The committee further recognizes that transporting neonates to centers for the sole purpose of obtaining conventional EEG monitoring may be detrimental to some patients and is not currently considered a standard of care.

Acknowledgements

The authors thank the following individuals for their valuable input during the development of this manuscript: John Barks, Hannah Glass, Cecil Hahn, Terrie Inder, Lawrence Hirsch, Joseph Sullivan, and Robert White.

References:

1. Clancy RR, Sharif U, Ichord R, Spray TL, Nicolson S, Tabbutt S, et al. Electrographic neonatal seizures after infant heart surgery. *Epilepsia*. 2005; **46**(1): 84-90.
2. Eriksson M, Zetterstrom R. Neonatal convulsions: incidence and causes in the Stockholm area. *Acta Paediatr Scand*. 1979; **68**: 807-11.
3. Gluckman PD, Wyatt JS, Azzopardi D, Ballard R, Edwards AD, Ferriero DM, et al. Selective head cooling with mild systemic hypothermia after neonatal encephalopathy: multicentre randomised trial. *Lancet*. 2005; **365**: 663-70.
4. Lanska MJ, Lanska DJ, Baumann RJ, Kryscio RJ. A population-based study of neonatal seizures in Fayette County, Kentucky. *Neurology*. 1995; **45**: 724-32.
5. Ronen GM, Penney S, Andrews W. The epidemiology of clinical neonatal seizures in Newfoundland: a population-based study. *Journal of Pediatrics*. 1999; **134**: 71-5.
6. Saliba RM, Annegers FJ, Waller DK, Tyson JE, Mizrahi EM. Incidence of neonatal seizures in Harris County, Texas, 1992-1994. *American Journal of Epidemiology*. 1999; **150**(7): 763-9.
7. Clancy RR, Legido ADL. Occult neonatal seizures. *Epilepsia*. 1988; **29**: 256-61.
8. Murray DM, Boylan GB, Ali I, Ryan CA, Murphy BP, Connolly S. Defining the gap between electrographic seizure burden, clinical expression and staff recognition of neonatal seizures. *Arch Dis Child Fetal Neonatal Ed*. 2008; **93**: F187-91.
9. McBride MC, Laroia N, Guillet R. Electrographic seizures in neonates correlate with poor neurodevelopmental outcome. *Neurology*. 2000; **55**: 506-14.
10. Wyatt JS, Gluckman PD, Liu PY, Azzopardi D, Ballard R, Edwards AD, et al. Determinants of outcomes after head cooling for neonatal encephalopathy. *Pediatrics*. 2007; **119**: 912-21.
11. Painter MJ, Scher MS, Stein AD, Armatti S, Wang Z, Gardiner JC, et al. Phenobarbital compared with phenytoin for the treatment of neonatal seizures. *New England Journal of Medicine*. 1999; **341**: 485-9.
12. Rennie JM, GB B. Treatment of neonatal seizures. *Arch Dis Child Fetal Neonatal Ed*. 2007; **92**: F148-F50.
13. Silverstein FS, Ferriero DM. Off-label use of antiepileptic drugs for the treatment of neonatal seizures. *Pediatric Neurology*. 2008; **39**: 77-9.
14. Cherian PJ, Blok JH, Swarte RM, Govaert P, Visser GH. Heart rate changes are insensitive for detecting postasphyxial seizures in neonates. *Neurology*. 2006; **67**(12): 2221-3.
15. Scher MS, Aso K, Beggarly ME, Hamid My, Steppe DA, Painter MJ. Electrographic seizures in preterm and full-term neonates: clinical correlates, associated brain lesions, and risk for neurologic sequelae. *Pediatrics*. 1993; **91**: 128-34.
16. Scher MS, Alvin J, Gaus L, Minnigh B, Painter MJ. Uncoupling of EEG-clinical neonatal seizures after antiepileptic drug use. *Pediatric Neurology*. 2003; **28**: 277-80.
17. Bye AME, Flanagan D. Spatial and temporal characteristics of neonatal seizures. *Epilepsia*. 1995; **36**(10): 1009-16.
18. Pisani F, Copioli C, Di Gioia C, Turco E, Sisti L. Neonatal seizures: relation of ictal video-electroencephalography (EEG) findings with neurodevelopmental outcome. *Journal of Child Neurology*. 2008; **23**(4): 394-8.

19. Clancy RR, Chung HG. EEG changes during recovery from acute severe neonatal citrullinemia. *Electroencephalography and Clinical Neurophysiology*. 1991; **78**(3): 222-7.
20. Scher MS. *Neonatal Electroencephalography*: William & Wilkins; 2005.
21. Sarnat HB, Sarnat MS. Neonatal encephalopathy following fetal distress. A clinical and electroencephalographic study. *Archives of Neurology*. 1976; **33**(10): 696-705.
22. Holmes GL, Lombroso CT. Prognostic value of background patterns in the neonatal EEG. *Journal of Clinical Neurophysiology*. 1993; **10**(3): 323-52.
23. Scher MS. Ontogeny of EEG-sleep from neonatal through infancy periods. *Sleep Med*. 2008; **9**(6): 615-36.
24. Hankins GD, Speer M. Defining the pathogenesis and pathophysiology of neonatal encephalopathy and cerebral palsy. *Obstetrics and Gynecology*. 2003; **102**(3): 628-36.
25. Scher MS. Automated EEG-sleep analyses and neonatal neurointensive care. *Sleep Med*. 2004; **5**(6): 533-40.
26. Guerit JM, Amantini A, Amodio P, Andersen KV, Butler S, de Weerd A, et al. Consensus on the use of neurophysiological tests in the intensive care unit (ICU): electroencephalogram (EEG), evoked potentials (EP), and electroneuromyography (ENMG). *Neurophysiol Clin*. 2009; **39**(2): 71-83.
27. Monod N, Pajot N, Guidasci S. The neonatal EEG: statistical studies and prognostic value in full-term and pre-term babies. *Electroencephalogr Clin Neurophysiol*. 1972; **32**(5): 529-44.
28. Tharp BR, Cukier F, Monod N. The prognostic value of the electroencephalogram in premature infants. *Electroencephalogr Clin Neurophysiol*. 1981; **51**(3): 219-36.
29. Epstein CM. Guidelines Two: Minimum technical standards for pediatric electroencephalography. *Journal of Clinical Neurophysiology*. 2006; **23**(2): 92-6.
30. Hellström-Westas L, de Vries LS, Rosen I. *Atlas of amplitude-integrated EEGs in the newborn*. 2 ed. London, UK: Informa Healthcare; 2008.
31. Wusthoff CJ, Shellhaas RA, Clancy RR. Limitations of single-channel EEG on the forehead for neonatal seizure detection. *Journal of Perinatology*. 2009; **29**(3): 237-42.
32. Rennie JM, Chorley G, Boylan GB, Pressler R, Nguyen Y, Hooper R. Non-expert use of the cerebral function monitor for neonatal seizure detection. *Arch Dis Child Fetal Neonatal Ed*. 2004; **89**: F37-F40.
33. Shellhaas RA, Saoita AI, Clancy RR. The Sensitivity of amplitude-integrated EEG for neonatal seizure detection. *Pediatrics*. 2007; **120**(4): 770-7.
34. Shah DK, Mackay MT, Lavery S, Watson S, Harvey SA, Zempel J, et al. Accuracy of bedside electroencephalographic monitoring in comparison with simultaneous continuous conventional electroencephalography for seizure detection in term infants. *Pediatrics*. 2008; **121**: 1146-54.
35. Stewart CP, Otsubo H, Ochi A, Sharma R, Hutchison JS, Hahn CD. Seizure identification in the ICU using quantitative EEG displays. *Neurology*. 2010; **75**(17): 1501-8.
36. Bourez-Swart MD, van Rooij L, Rizzo C, de Vries LS, Toet MC, Gebbink TA, et al. Detection of subclinical electroencephalographic seizure patterns with multichannel

- amplitude-integrated EEG in full-term neonates. *Clinical Neurophysiology*. 2009; **120**: 1916-22.
37. Nash KB, Bonifacio SL, Glass HC, Sullivan JE, Barkovich AJ, Ferriero DM, et al. Video-EEG monitoring in newborns with hypoxic-ischemic encephalopathy treated with hypothermia. *Neurology*. 2011; **76**: 556-62.
 38. Laroia N, Guillet R, Burchfiel J, McBride MC. EEG Background as predictor of electrographic seizures in high-risk neonates. *Epilepsia*. 1998; **39**(5): 545-51.
 39. Shellhaas RA, Clancy RR. Characterization of neonatal seizures by conventional and single channel EEG. *Clinical Neurophysiology*. 2007; **118**: 2156-61.
 40. Korff C, Nordli DR. Do generalized tonic-clonic seizures in infancy exist? *Neurology*. 2005; **65**(11): 1750-3.
 41. Ponnusamy V, Nath P, Bissett, et al. Current availability of cerebral function monitoring and hypothermia therapy in UK neonatal units. *Arch Dis Child Fetal Neonatal Ed*. 2010; **95**: F383-4.
 42. Boylan GB, Burgoyne L, Moore C, O'Flaherty B, Rennie JM. An international survey of EEG use in the neonatal intensive care unit. *Acta Paediatr*. 2010; **99**: 1150-5.
 43. Toet MC, PMA. L. Brain monitoring in neonates. *Early Human Development*. 2009; **85**(2): 77-84.
 44. Filan PM, Inder TE, Anderson PJ, Doyle LW, Hunt RW. Monitoring the neonatal brain: a survey of current practice among Australian and New Zealand neonatologists. *Journal of Paediatrics and Child Health*. 2007; **43**: 557-9.
 45. Hellström-Westas L, Rosen I, de Vries LS, Greisen G. Amplitude-integrated EEG classification and interpretation in preterm and term infants. *Neoreviews*. 2006; **7**(2): e76-e87.
 46. van Rooij LGM, Toet MC, van Huffelen AC, Groenendaal F, Laan W, Zecic A, et al. Effect of treatment of subclinical neonatal seizures detected with aEEG: randomized, controlled trial. *Pediatrics*. 2010; **125**: e358-e66.
 47. al Naqeeb N, Edwards AD, Cowan FM, Azzopardi D. Assessment of neonatal encephalopathy by amplitude-integrated electroencephalography. *Pediatrics*. 1999; **103**(6): 1263-71.
 48. Hellström-Westas L, Rosen I, Svenningsen NW. Predictive value of early continuous amplitude integrated EEG recordings on outcome after severe birth asphyxia in full term infants. *Arch Dis Child*. 1995; **72**: F34-F8.
 49. Shalak LF, Laptook AR, Velaphi SC, Perlman JM. Amplitude-integrated electroencephalography coupled with an early neurologic examination enhances prediction of term infants at risk for persistent encephalopathy. *Pediatrics*. 2003; **111**(2): 351-7.
 50. Toet MC, Hellström-Westas L, Groenendaal F, Eken P, de Vries LS. Amplitude-integrated EEG 3 and 6 hours after birth in full term neonates with hypoxic-ischaemic encephalopathy. *Arch Dis Child Fetal Neonatal Ed* 1999; **81**: 19-23.
 51. Azzopardi DV, Strohm B, Edwards AD, Dyet L, Halliday HL, Juszczak E, et al. Moderate hypothermia to treat perinatal asphyxial encephalopathy. *New England Journal of Medicine*. 2009; **361**: 1349-58.
 52. Sarkar S, Barks JD, Donn SM. Should amplitude-integrated electroencephalography be used to identify infants suitable for hypothermic neuroprotection? *Journal of Perinatology*. 2008; **28**: 117-22.

53. Abend NS, Dlugos D, Herman ST. Neonatal seizure detection using multichannel display of envelope trend. *Epilepsia*. 2008; **49**(2): 349-52.
54. Temko A, Thomas E, Boylan GB, Marnane W, Lightbody G. An SVM-Based system and its performance for detection of seizures in neonates. *Conf Proc IEEE Eng Med Biol Soc*. 2009; **2009**: 2643-6.
55. Mitra J, Glover JR, Ktonas PY, Kumar AT, Mukherjee A, Karayiannis NB, et al. A Multistage system for the automated detection of epileptic seizures in neonatal electroencephalography. *Journal of Clinical Neurophysiology*. 2009; **26**(4): 218-26.